



# Clinical Weekly - 185<sup>th</sup> Edition

#JOURNALTUESDAY - by Abi Peck

A systematic review of potential long term effects of sports related concussion. [Download here](#)

**1. Did the review address a clearly focused question?**

Yes, what are the long term effects of sports related concussion?

Retired athlete population

Neurological examination, neuroimaging, cognitive assessment, neuropathology.

**2. Did the authors look for the right type of papers?**

Yes, systematic review of databases using keywords

**3. Do you think all the important, relevant studies were included?**

Yes, used medical and sports search engines. Only looked at peer reviewed articles which could predispose the paper to the risk of publication bias and only used English language papers which could lead to cultural bias.

**4. Did the review's authors do enough to assess the quality of the included studies?**

Yes, citations were independently screened by two authors and agreed by a third. The level of evidence was assessed using Downs and Black checklist by two authors.

**5. If the results of the review have been combined, was it reasonable to do so?**

Yes, studies were grouped together into relevant categories.

**6. What are the overall results of the review?**

Multiple concussions have been associated with increased risk factors for developing cognitive impairments and mental health problems.

**7. How precise are the results?**

Study did not use confidence intervals, statistical or clinical significance values in discussion of results.

**8. Can the results be applied to the local population?**

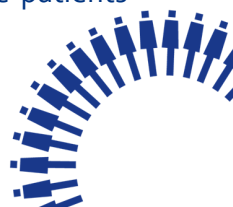Results can be applied to the retired sporting population but more research is needed.

**9. Were all important outcomes considered?**

Yes, but perhaps more longitudinal studies are needed to rule out extraneous variables.

**10. Are the benefits worth the harms and costs?**

No reported harms to completing the systematic review. Within some of the studies some patients were exposed to radiation with imaging which is considered harmful.



## #NEWSOFTHEWEEK - by Liz Wright

### 1. Clinical Examination, Diagnostic Imaging, and Testing of Athletes With Groin Pain: An Evidence-Based Approach to Effective Management

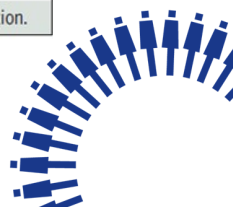
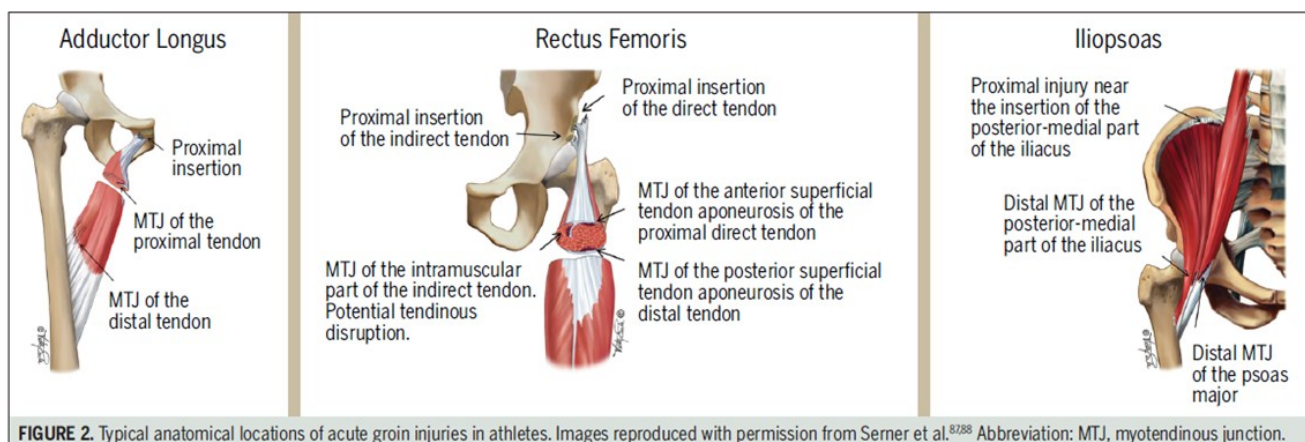
Limited evidence based on clinical trials comparing nonsurgical to surgical interventions for groin pain in athletes is evident. However, there was a recent systematic review which indicated nonsurgical and surgical interventions have similar return-to-play times. Generally, it is recommended nonsurgical management as the first line of treatment for athletes with hip and groin pain, as in many cases this will result in satisfactory results.

For athletes with adductor-related groin pain, there is level 1 evidence that a supervised active approach to rehabilitation, results in a higher success of return to play when compared to the use of passive physical therapy modalities. The use of adjunct treatments, such as manual adductor manipulation or shockwave therapy, in addition to exercises seems to result in a faster return to play, but not higher overall treatment success, than a supervised active physical training program alone.

For athletes with inguinal-related groin pain, laparoscopic hernia surgery has been shown to result in lower pain and a higher % returning to play than nonsurgical treatment in a RCT. However, nonsurgical treatment with exercises and injections showed some promise, with 50% of participants fully recovered after 1 year in this same RCT. Hence a non-operative approach is advised first given the risk of possible surgical complications.

There is no high-level evidence to support or refute the use of exercise or other nonsurgical treatments to address iliopsoas related groin pain. Therefore it is proposed to base treatment on impairments and functional deficits. For athletes with hip-related groin pain, suggested management strategies (specifically FAI syndrome) include rehabilitation, medication, and surgery (particularly arthroscopy). There is no high-level evidence supporting the superiority of any single approach. For athletes with multiple entities, specific attention toward impairments, function, and performance can be helpful.

<https://www.jospt.org/doi/pdf/10.2519/jospt.2018.7850>





# Clinical Weekly - 185<sup>th</sup> Edition

## #NEWSOFTHEWEEK - by Liz Wright

### 2. Education plus exercise versus corticosteroid injection use versus a wait and see approach on global outcome and pain from gluteal tendinopathy: prospective, single blinded, randomised clinical trial (open access)

Comparison is made between: 14 sessions over 8 weeks load management programme + education + exercise vs 1 corticosteroid injection vs no treatment, on pain and global improvement in individuals with gluteal tendinopathy. This RCT provides evidence that education + exercise leads to greater pain relief and global improvement than corticosteroid injection use or no treatment by 8 weeks. After 52 weeks, rates of improvement remained higher for education plus exercise than for corticosteroid injection use. These results support the use of education + exercise as an effective management approach for gluteal tendinopathy. Until now, although exercise is recommended for tendinopathies, there have been no RCTs which have investigated its effects in gluteal tendinopathy.

<https://www.bmj.com/content/361/bmj.k1662>

<https://bit.ly/2HFnVDD>

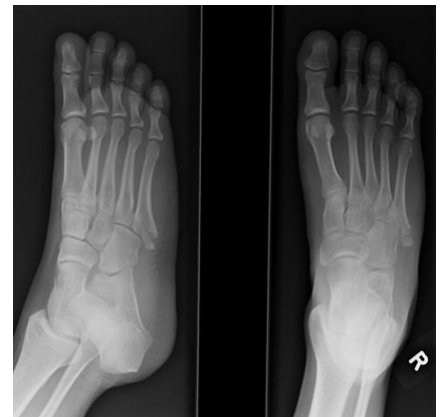## #FRACTUREFRIDAY BY SCOTT ROWBOTHAM

### Pseudo-Jones Fracture/ Dancer Fracture

This is an avulsion fracture of the 5th metatarsal styloid. It is one of the most common foot avulsion injuries accounting for over 90% of fractures of the base of the 5th metatarsal. It is also known as a tennis fracture

### **Mechanism of Injury**

As the fracture terms suggest it can be an overuse and stress related injury or from a forcible inversion and plantar flexion of the foot. There is differing opinion of the cause of the avulsion. It can be attributed to the avulsion of the peroneus brevis insertion or the lateral cord of the plantar aponeurosis inserting to the base of the metatarsal.



### **Imaging**

X-ray is sufficient but a lateral image must be obtained to include an appropriate angle of the 5th metatarsal.

### **Treatment and prognosis**

These fractures can be treated well conservatively through offloading or immobilisation followed by progressive gait re-education, strengthening and proprioception.

If the fracture is large displaced fragments with intra-articular extension then operative fixation may be indicated.

<https://radiopaedia.org/articles/avulsion-fracture-of-the-5th-metatarsal-styloid>

